


DEN Video Article

Esophagogastroduodenoscopy procedure using disposable endoscope to detect the cause of melena in a patient with COVID-19

1 Fenghua Xu,¹ Yunsheng Yang² and Zhen Ding¹ 

¹Department of Gastroenterology, Union Hospital, Tongji Medical College, Huazhong University of Science and Technology, Wuhan and ²Department of Gastroenterology and Hepatology, Chinese PLA General Hospital, Beijing, China

BRIEF EXPLANATION

A 55-YEAR-OLD MAN was admitted in a day in February with fever for 1-week, dyspnea for 4 days and diarrhea for 5 days. The patient was diagnosed as COVID-19 with hypoxemia, and assigned to the intensive care unit (ICU) for respiratory support. The respiratory syndrome of the patient improved after treatment. However, after 1 month the patient presented with severe anemia with

melena. The level of hemoglobin decreased gradually from 143 g/L at admission to 71 g/L on 43 days after the date of admission, and the fecal occult blood detection confirmed gastrointestinal (GI) bleeding. Emergent endoscopy was necessary to reveal the cause of bleeding. We decided to perform the upper GI endoscopy using a disposable endoscope (XZING-W200B; Huizhou Xzing Technology Co., Ltd, Huizhou, Guangdong, China, Fig. 1A). Its approximate specifications are as follows: two light-emitting

COLOR

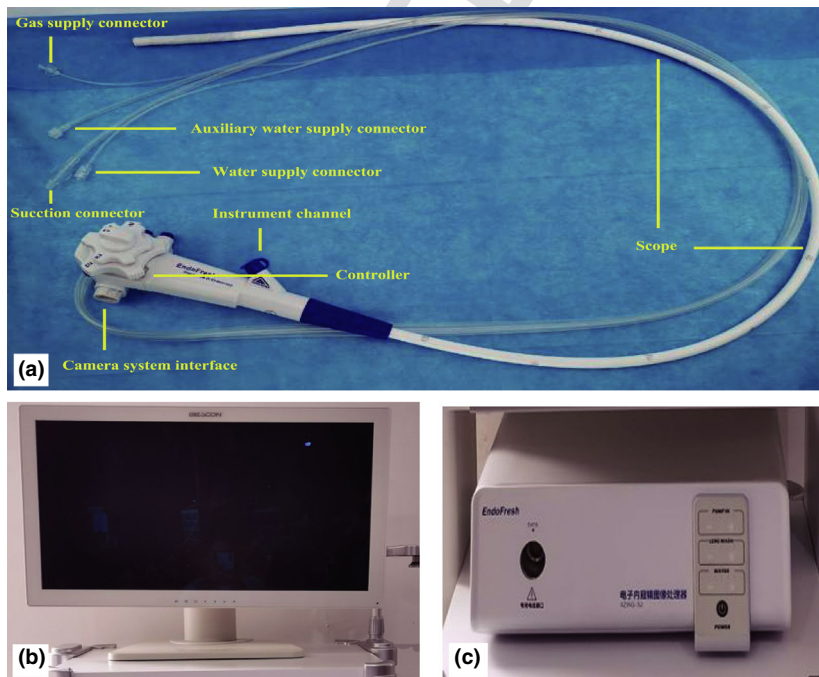
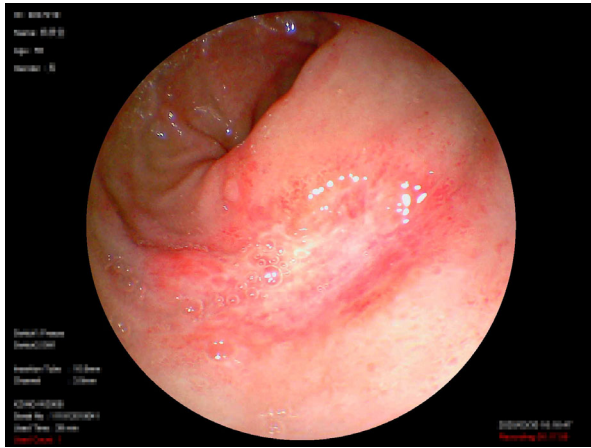


Figure 1 (A) appearance of disposable gastroscopy; (B) the viewer program; (C) the processor.

Corresponding: Zhen Ding, Department of Gastroenterology, Union Hospital, Tongji Medical College, Huazhong University of Science and Technology, 1277 Jiefang Avenue, Wuhan, Hubei Province 430022, China. Email: docd720@126.com
 Received 25 July 2020; accepted 9 September 2020.

D E N	13840	Journal Code	CE:	FE: Deivapriyadharsini D.
			Dispatch: 1.10.20	No. of pages: 2
Manuscript No.				



4 6 **Figure 2** Duodenal ulcer was found in the procedure.

diodes (LEDs), 11.0-mm-diameter tube with 1300 mm length, 3.0-mm diameter channel, a 110° view angle, 180° bending angles for up, and 160° bending angles for down, left, and right each. The probe (scope) is manipulated by the controller that is connected to the processor (XZING-S2, Fig. 1C) with a viewer program (Fig. 1B). In ICU, the emergent endoscopy was performed and an ulcer was detected in the duodenal bulb (Fig. 2, Video S1). Esophagogastroduodenoscopy (EGD) is recommended in the early stage of GI bleeding, however, the study identified the receptor of SARS-CoV-2 (ACE-2) expressing in the GI tract and some researchers have isolated infectious virus from patient stool.^{1,2} Therefore, the endoscope might be contaminated by digestive fluid which can spread the virus to the operator and cleaner. During the COVID-19 pandemic, the appropriate use of personal protective equipment (PPE) and simple barrier device can prevent SARS-CoV-2 infection in endoscopy units.^{3,4} The use of a disposable endoscope is

also a preferred option for minimizing the risk of contact transmission.⁵

Authors declare no conflicts of interest for this article.

ACKNOWLEDGMENT

WE THANK RONG Lin, Liping Sheng, Jun Liu, Shi Liu, erchuan Wang, Ge Cao, Xiaohua Hou and Huizhou Xzing Technology Co., Ltd for assistance with this paper.

REFERENCES

- 1 Zhou J, Li C, Liu X *et al.* Infection of bat and human intestinal organoids by SARS-CoV-2. *Nat Med* 2020; **26**: 1077–83.
- 2 Matthai J, Shanmugam N, Sobhan P. Coronavirus disease (COVID-19) and the gastrointestinal system in children. *Indian Pediatr* 2020; **57**: 533–5.
- 3 Onoyama T, Isomoto H. COVID-19 and gastrointestinal endoscopy: importance of reducing SARS-CoV-2 infection risks of medical workers and preserving personal protective equipment resources. *Dig Endosc* 2020; **32**: 732–5.
- 4 Suzuki S, Kusano C, Ikehara H. Simple barrier device to minimize facial exposure of endoscopists during COVID-19 pandemic. *Dig Endosc* 2020; **32**: e118–9.
- 5 Mayinger B, Strenkert M, Hochberger J, Martus P, Kunz B, Hahn EG. Disposable-sheath, flexible gastroscope system versus standard gastroscopes: a prospective, randomized trial. *Gastrointest Endosc* 1999; **50**: 461–7.

SUPPORTING INFORMATION

ADDITIONAL SUPPORTING INFORMATION may be found in the online version of this article at the publisher's web site.

Video S1 Using disposable endoscope to detect the cause of melena in a patient with COVID-19.